

Rapid and Durable Complete Remission of Refractory AITL with Azacitidine Treatment in Absence of TET2 Mutation or Concurrent MDS

Gareth P. Gregory^{1,2}, Michael Dickinson^{3,4}, Costas K. Yannakou^{3,4,5}, Jonathan Wong^{1,2}, Piers Blombery^{3,4}, Greg Corboy^{1,2}, Lev Kats^{4,6}, Tim M.E. Crozier^{1,2}, Beena Kumar^{1,2}, H. Miles Prince^{3,4,5}, Stephen S. Opat^{1,2}, Jake Shortt^{1,2,4}

Correspondence: Gareth P. Gregory (e-mail: gareth.gregory@monashhealth.org).

Angioimmunoblastic T-cell lymphoma (AITL) is a rare disease entity associated with poor prognosis and no improvement in overall survival over the last 20 years.¹ The genomic landscape of AITL has revealed frequent mutation of epigenetic modifiers *TET2* (76%), *DNMT3A* (33%) and *IDH2* (20%), genetic mutations that may be predictive of response to hypomethylating agents (HMA) in myelodysplastic syndromes.²⁻⁴ Genomic profiling has also demonstrated *TET2* mutations to be present in both malignant and non-malignant hematopoietic cells of affected individuals, suggesting loss of *TET2* to be the initiating

mutation, following which secondary mutations direct the lineage phenotype of subsequent malignancy [eg, secondary *RHOA* mutations in AITL versus myeloid-lineage associated mutations in genes such as *RAS* leading to myelodysplasia (MDS) / chronic myelomonocytic leukemia (CMML)].^{3,5} The potential efficacy of HMAs in the treatment of AITL has emerged from the observation of regressing lymphadenopathy in patients treated for their concomitant MDS, however, such AITL responses may have been confounded by frequent concurrent rituximab administration for Epstein-Barr virus (EBV)-reactivation which is characteristic of this disease.⁶⁻⁸

Herein, we describe the case of a rapid, durable and complete response to azacitidine in a patient with AITL previously refractory to 10 lines of therapy. Next generation sequencing studies performed on the patient's tumor did not detect mutations or copy number alteration in recurrently mutated genes of AITL including *TET2*, *IDH2*, *RHOA* and/or *DNMT3A*. In addition, the patient did not have a concomitant diagnosis of MDS or receive treatment for EBV reactivation. We posit that the therapeutic benefit of azacitidine in AITL is not dependent on the presence of high-frequency recurrent mutations of canonical DNA methylation regulators, or at the very least that therapeutic benefit may still be derived in the absence of such mutations. These findings warrant prioritization of prospective studies of HMAs for patients with AITL irrespective of the mutational profile or presence of concomitant MDS.

A 54-year old man was referred to our service in 2011 with a rapidly enlarging left inguinal nodal mass and B-symptoms. Lymph node biopsy confirmed a diagnosis of AITL (Fig. 1A) and staging investigations confirmed Ann-Arbor stage II disease. The blood and bone marrow examinations exhibited marked eosinophilia, but no evidence of lymphoma, dysplasia or monocytosis. From 2011 to 2013, his disease was refractory to nine lines of therapy (Table 1) with only transient partial responses achieved at best. He was then enrolled in a phase II clinical trial of panobinostat (NCT01658241), however, he did not achieve an objective response to this agent. By 2014, the patient had received 10 lines of failed therapies in which he had never achieved a complete remission.

Given the emergent publications of the AITL genome, a rationale for re-purposing of hypomethylator therapy in this disease context was postulated.^{2,3} Following approval from our institutional Drug & Therapeutics Committee and with

Gareth P. Gregory and Michael Dickinson co-first authors.

Stephen S. Opat and Jake Shortt co-senior authors.

All authors contributed to the writing of the manuscript and approved the final version. GPG, CKY, BK, PB and JW compiled the figures. CKY and PB performed the genomic analysis. GPG, JW, MD, TMEC, HMP, SSO and JS were all involved in the clinical management of the patient.

Disclosures: GPG: Celgene, research funding. MD: Celgene, research funding, honoraria. HMP: Celgene, advisory board, research funding. SSO: Celgene, advisory board. JS: Astex, research funding; Celgene, advisory board, speaker's bureau.

Azacitidine is not licensed in Australia for treatment of T-cell malignancies.

The panobinostat clinical trial was funded by a grant from the Victorian Cancer Agency (NCT01658241).

The authors have indicated they have no potential conflicts of interest to disclose.

¹Monash Health, Clayton, Victoria, Australia

²School of Clinical Sciences at Monash Health, Monash University, Clayton, Victoria, Australia

³Clinical Haematology, Peter MacCallum Cancer Centre and Royal Melbourne Hospital, Parkville, Victoria, Australia

⁴Sir Peter MacCallum Department of Oncology, University of Melbourne, Parkville, Victoria, Australia

⁵Department of Molecular Oncology and Cancer Immunology, Epworth Healthcare, East Melbourne, Victoria, Australia

⁶Research Division, Peter MacCallum Cancer Centre, Parkville, Victoria, Australia.

Copyright © 2019 the Author(s). Published by Wolters Kluwer Health, Inc. on behalf of the European Hematology Association. This is an open access article distributed under the Creative Commons Attribution License 4.0 (CCBY), which permits unrestricted use, distribution, and reproduction in any medium, provided the original work is properly cited.

HemaSphere (2019) 3:2(e187)

Received: 2 December 2018 / Received in final form: 23 January 2019 /

Accepted: 10 February 2019

Citation: Gregory GP, Dickinson M, Yannakou CK, Wong J, Blombery P, Corboy G, Kats L, Crozier TME, Kumar B, Prince HM, Opat SS, Shortt J. Rapid and Durable Complete Remission of Refractory AITL with Azacitidine Treatment in Absence of TET2 Mutation or Concurrent MDS. *HemaSphere*, 2019;3:2. <http://dx.doi.org/10.1097/HS9.0000000000000187>

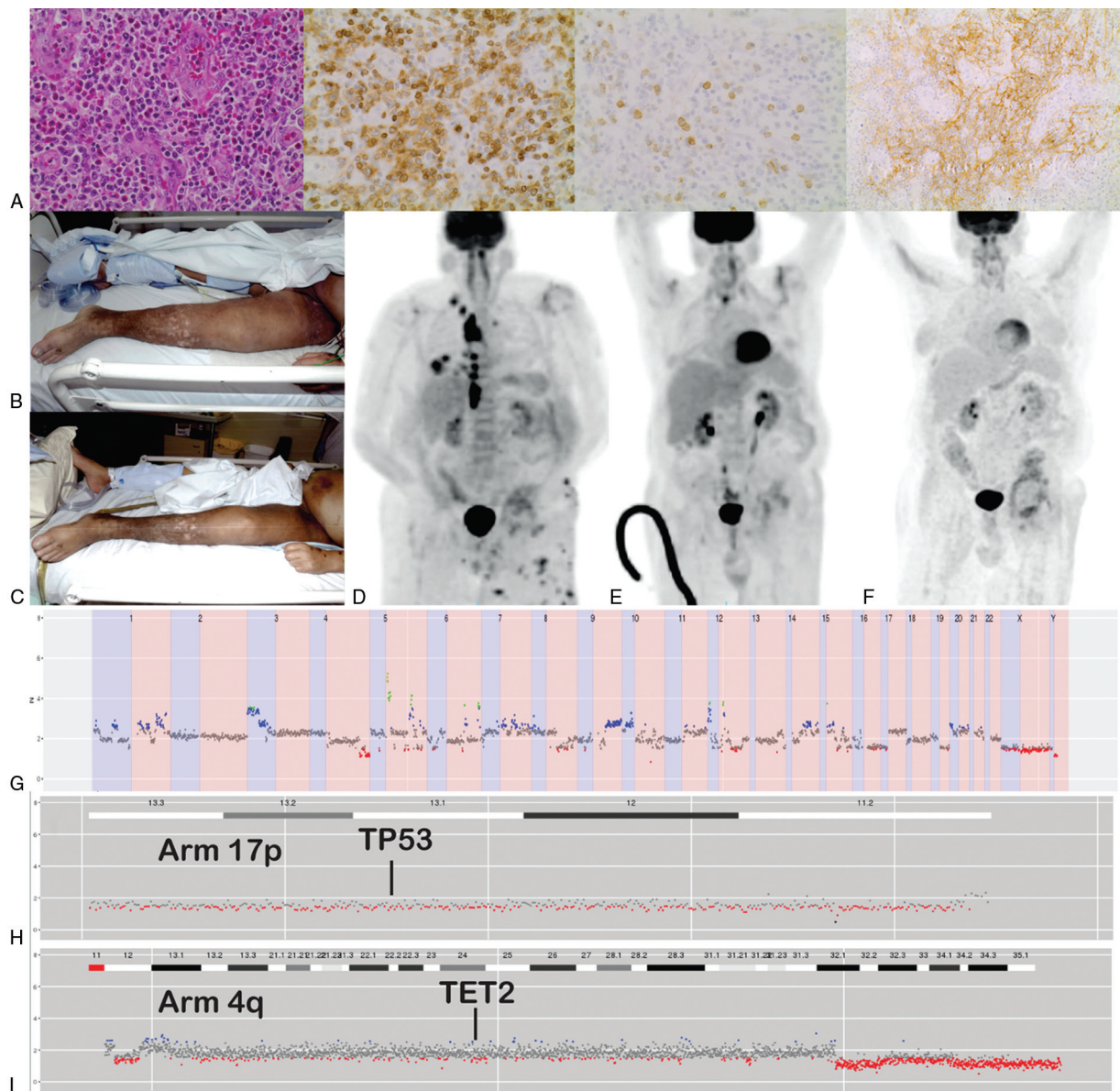


Figure 1. Diagnostic, clinical and genomic aspects of the case. (A) Diagnostic biopsy of the inguinal lymph node demonstrating an atypical lymphoid infiltrate and prominent high endothelial venules (far left, H&E stain 40x), positive staining of the lymphocytes for CD3 (inner left) and CD10 (inner right) and an irregular, expanded dendritic cell population positively staining for CD21 (far right). (B) Clinical photograph demonstrating lymphangitis and cutaneous disease prior to therapy on day 1 cycle 1, and (C) clinical response 11 days later. (D) Positron-emission tomography scan prior to azacitidine, (E) post-cycle three and (F) 3 years later demonstrating ongoing complete metabolic response. (G) Genome-wide copy number detection demonstrating significant copy number variation throughout the tumor genome. (H) Copy number detection demonstrating 17p monosomy. (I) Copy number detection demonstrating absence of significant copy number alteration affecting TET2.

Australian TGA notification the patient consented to off-label treatment with azacitidine. Prior to commencement his disease had extranodal extension into the left femur with cutaneous involvement and extensive lymphedema due to tumor-related obstruction (Fig. 1B) and the patient was admitted to the intensive care unit following respiratory arrest secondary to viral pneumonitis (H1N1 and Influenza A) complicated by acute cardiomyopathy and polymicrobial chest sepsis for which he was requiring physiological support.

During the first cycle of azacitidine (75 mg/m² by subcutaneous injection given days 1–7)⁹ the patient had a rapid response with regression of cutaneous lesions and resolution of lymphedema following large diuresis independent of altered cardiovascular

status (Fig. 1C). He subsequently achieved a complete metabolic remission (CMR) after three cycles of therapy (Fig. 1D-E). He is currently in ongoing CMR after 60 cycles of azacitidine (Fig. 1F).

DNA was extracted from fresh cutaneous tissue obtained immediately prior to treatment with panobinostat and sequenced using a hybridization-based NGS panel covering approximately 300 genes recurrently mutated in hematological malignancy.¹⁰ A sequence variant in TP53 (NM_000546.5: c.376_394del, p.(Tyr126Argfs*38)) predicted to result in a truncated protein product was detected. In addition a missense mutation was detected in NCOR1 (NM_001190440.1: c.4627G>A, p.(Glu1543Lys)). Analysis of whole genome copy number was performed using off-target reads as described

Table 1
Therapies administered 2011 to 2018.

Date	Therapy
3/2011	Cyclophosphamide, doxorubicin, vincristine, etoposide and prednisolone (CHOEP) – 6 cycles
7/2011	Ifosfamide, etoposide and cytarabine (IVAC) – 1 cycle ¹⁴
9/2011	Involved field radiotherapy - 40 Gray / 20 fractions
11/2011	Brentuximab vedotin – 4 cycles
4/2012	Ciclosporin
6/2012	Bortezomib, doxorubicin and dexamethasone (PAD) – 2 cycles ¹⁵
1/2013	Involved field radiotherapy - 30 Gray / 15 fractions
5/2013	Romidepsin
8/2013	Gemcitabine
12/2013	Panobinostat
3/2014	Azacitidine

previously.¹⁰ This revealed multiple copy number abnormalities throughout the genome (Fig. 1G) but specifically a copy number loss involving TP53 (Fig. 1H) and no significant copy number alteration affecting TET2 (Fig. 1I). Importantly, no candidate pathogenic mutations were detected in the entire coding regions of TET1, TET2, TET3, RHOA, DNMT3A, and IDH2. The percentage of the TET2 gene covered was 100% with a mean coverage of 486X and 99.43% of the gene covered >100X.

Next generation sequencing technologies have rapidly advanced our understanding of the genetic landscape of incurable hematological diseases such as AITL. The recognition of frequent somatic mutation of regulators of DNA methylation² has revealed an unanticipated overlap with the molecular signature of MDS, an HMA-responsive disease. The co-occurrence of clonally-related MDS, in particular CMML, is increasingly recognized as an AITL disease association. Although the intraclonal architecture has not been mapped at a single-cell level, it is postulated founder mutations of DNA methylation regulators may seed progeny with both MDS or T-cell lymphoma phenotypes, depending on the nature of secondary mutational events.³ This hypothesis is supported by a recent case report of an individual with AITL and acute myeloid leukemia, in which the relative variant allele frequencies in the pre-leukemic bone marrow and leukemic bone marrow suggested clonal evolution from a common founder mutation.⁵ From a clinical perspective, concurrent CMML may be unrecognized, due to the presumption of ‘reactive’ monocytosis in the context of immune dysregulation and the attribution of cytopenias to bone marrow infiltration by lymphoma. Indeed, the first reported case of an objective response to azacitidine in AITL was in a patient being treated primarily for CMML and with concurrent rituximab for EBV reactivation.⁶

The mechanism of action of HMAs in MDS remains incompletely understood. TET2 mutations predict a marginally higher response rate to HMA, but significant clinical responses are also observed in the absence of TET2 loss. The delay between rapid changes in DNA methylation and clinical remission (which may take 6 months) is potentially explained by secondary immune mediated effects.¹¹ This hypothesis is supported by evidence from recent studies of DUSP22-rearranged anaplastic large cell lymphoma wherein the hypomethylated molecular signature was associated with an immunogenic phenotype.¹² Furthermore, peripheral T-cell lymphomas including AITL have recently been demonstrated to have a consistent methylation immunophenotype with absence of 5-hydroxymethylcytosine in malignant cells irrespective of the mutational profile including

TET2 mutational status, and it remains unclear as to whether this may confer specific sensitivity to HMAs.¹³

The present case is remarkable as the patient had disease that was refractory to multiple conventional and novel therapies and yet the response to azacitidine occurred within days of exposure and has been maintained for years thereafter in the absence of the somatic mutational profile we assumed was being ‘targeted’ (ie, TET2 or IDH2 mutant disease). This suggests an unanticipated synthetic-lethal interaction with lymphoma biology that is unrelated to the hypothesis-based application of an HMA and also independent of direct cytotoxicity in the setting of bi-allelic TP53 disruption. The tempo of response is also of interest as the total cellularity of an involved node/tissue with AITL is largely contributed by reactive cells in the microenvironment, and it is possible that the rapid clinical regression is an effect of HMA therapy on the microenvironment rather than purely cell-intrinsic to the malignant cells.

This case is noteworthy for genomic instability as evidenced by the complex CNV changes, and further studies assessing efficacy of HMA therapy in this setting may be warranted. In light of recent retrospective data suggesting a 75% response rate to azacitidine in AITL,⁸ further prospective evaluation of HMAs in T-cell lymphoma is imminent. Our exceptional responder indicates that mutational profiling, in particular TET2 status, should not be the basis of pre-selection for such studies and that even highly refractory disease can demonstrate dramatic and durable responses.

Acknowledgments

The authors wish to acknowledge the Monash Health Drug & Therapeutics Committee and Celgene for providing patient access to azacitidine, and the patient and their family for their consent to allow further diagnostic testing on their lymphoma.

References

- Xu B, Liu P. No Survival improvement for patients with angioimmunoblastic T-cell lymphoma over the past two decades: a population-based study of 1207 Cases. *Kato M, ed. PLoS One.* 2014;9:e92585–e92587.
- Odejide O, Weigert O, Lane AA, et al. A targeted mutational landscape of angioimmunoblastic T-cell lymphoma. *Blood.* 2014; 123:1293–1296.
- Sakata-Yanagimoto M, Enami T, Yoshida K, et al. Somatic RHOA mutation in angioimmunoblastic T cell lymphoma. *Nat Genet.* 2014;46:171–175.
- Cedena MT, Rapado I, Santos-Lozano A, et al. Mutations in the DNA methylation pathway and number of driver mutations predict response to azacitidine in myelodysplastic syndromes. *Oncotarget.* 2017;8: 106948–106961.
- Tiacci E, Venanzi A, Ascani S, et al. High-risk clonal hematopoiesis as the origin of AITL and NPM1-Mutated AML. *N Engl J Med.* 2018;379:981–984.
- Cheminant M, Bruneau J, Kosmider O, et al. Efficacy of 5-azacytidine in a TET2 mutated angioimmunoblastic T cell lymphoma. *Br J Haematol.* 2015;168:913–916.
- Saillard C, Guermouche H, Derriex C, et al. Response to 5-azacytidine in a patient with TET2-mutated angioimmunoblastic T-cell lymphoma and chronic myelomonocytic leukaemia preceded by an EBV-positive large B-cell lymphoma. *Hematol Oncol.* 2016;123:2636–2645.
- Lemonnier F, Dupuis J, Sujobert P, et al. Treatment with 5-azacytidine induces a sustained response in patients with angioimmunoblastic T-cell lymphoma. *Blood.* 2018;132:2305–2309.
- Silverman LR, Demakos EP, Peterson BL, et al. Randomized controlled trial of azacitidine in patients with the myelodysplastic syndrome: a study of the cancer and leukemia group B. *J Clin Oncol.* 2002;20: 2429–2440.

10. Blombery PA, Ryland GL, Markham J, et al. Detection of clinically relevant early genomic lesions in B-cell malignancies from circulating tumour DNA using a single hybridisation-based next generation sequencing assay. *Br J Haematol.* 2017;183:146–149.
11. Costantini B, Kordasti SY, Kulasekararaj AG, et al. The effects of 5-azacytidine on the function and number of regulatory T cells and T-effectors in myelodysplastic syndrome. *Haematologica.* 2013;98:1196–1205.
12. Luchtel RA, Dasari S, Oishi N, et al. Molecular profiling reveals immunogenic cues in anaplastic large cell lymphomas with DUSP22 rearrangements. *Blood.* 2018;132:1386–1398.
13. Lemonnier F, Poullot E, Dupuy A, et al. Loss of 5-hydroxymethylcytosine is a frequent event in peripheral T-cell lymphomas. *Haematologica.* 2018;103:e115–e118.
14. Mead GM, Sydes MR, Walewski J, et al. An international evaluation of CODOX-M and CODOX-M alternating with IVAC in adult Burkitt's lymphoma: results of United Kingdom Lymphoma Group LY06 study. *Ann Oncol.* 2002;13:1264–1274.
15. Oakervee HE, Popat R, Curry N, et al. PAD combination therapy (PS-341/bortezomib, doxorubicin and dexamethasone) for previously untreated patients with multiple myeloma. *Br J Haematol.* 2005;129:755–762.