

Dora Huang<sup>1</sup>, Jessica Rahme<sup>1</sup>, José Tomás Larach<sup>4</sup>, Edward Clarke<sup>1</sup>, Amrish Rajkomar<sup>2,3</sup>, Phillip Smart<sup>1-3</sup>, Satish Warriar<sup>2-4</sup>

<sup>1</sup>Department of General Surgery, Austin Health, Melbourne, Australia

<sup>2</sup>Department of Colorectal Surgery, St Vincent's Hospital, Melbourne, Australia

<sup>3</sup>General Surgery and Gastroenterology Clinical Institute, Epworth Healthcare

<sup>4</sup>Department of Surgery, Peter MacCallum Cancer Centre, Melbourne Australia

## BACKGROUND

Robotic compared to the laparoscopic approach to the right hemicolectomy, has been associated with:

- Decreased anastomotic complications
- Increased lymph node harvest
- Decreased length of stay
- Decreased conversion to open
- Comparable morbidity and 30-day mortality (1)

The intrinsic advantages of the robotic platform include better visualisation, intra-abdominal access and stability (2,3).

## CASE PRESENTATION

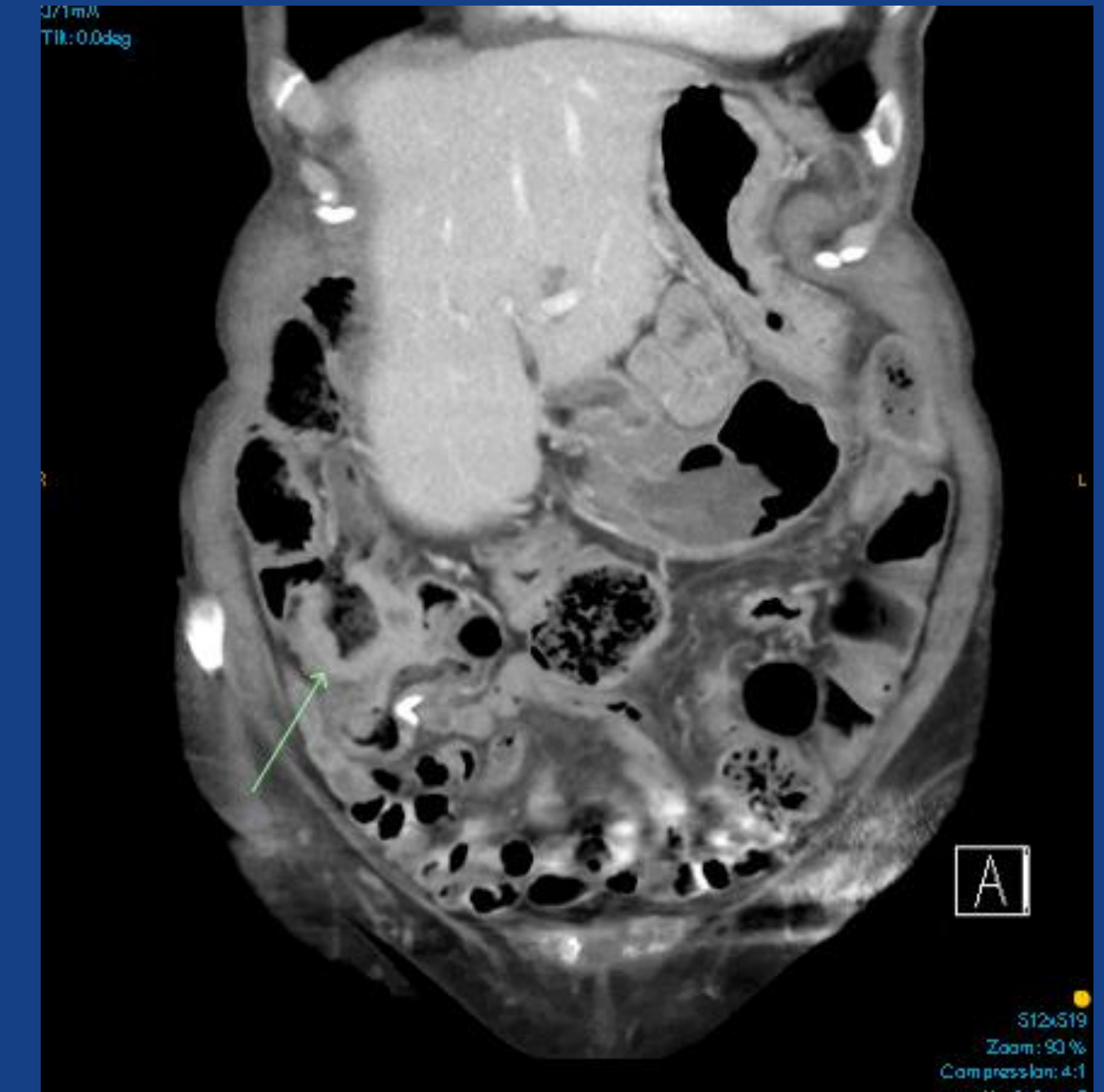83 year-old female

- Symptomatic anaemia (Hb 88 g/L)
- PHx: of cardiomyopathy and hypertension
- No FHx of bowel cancer

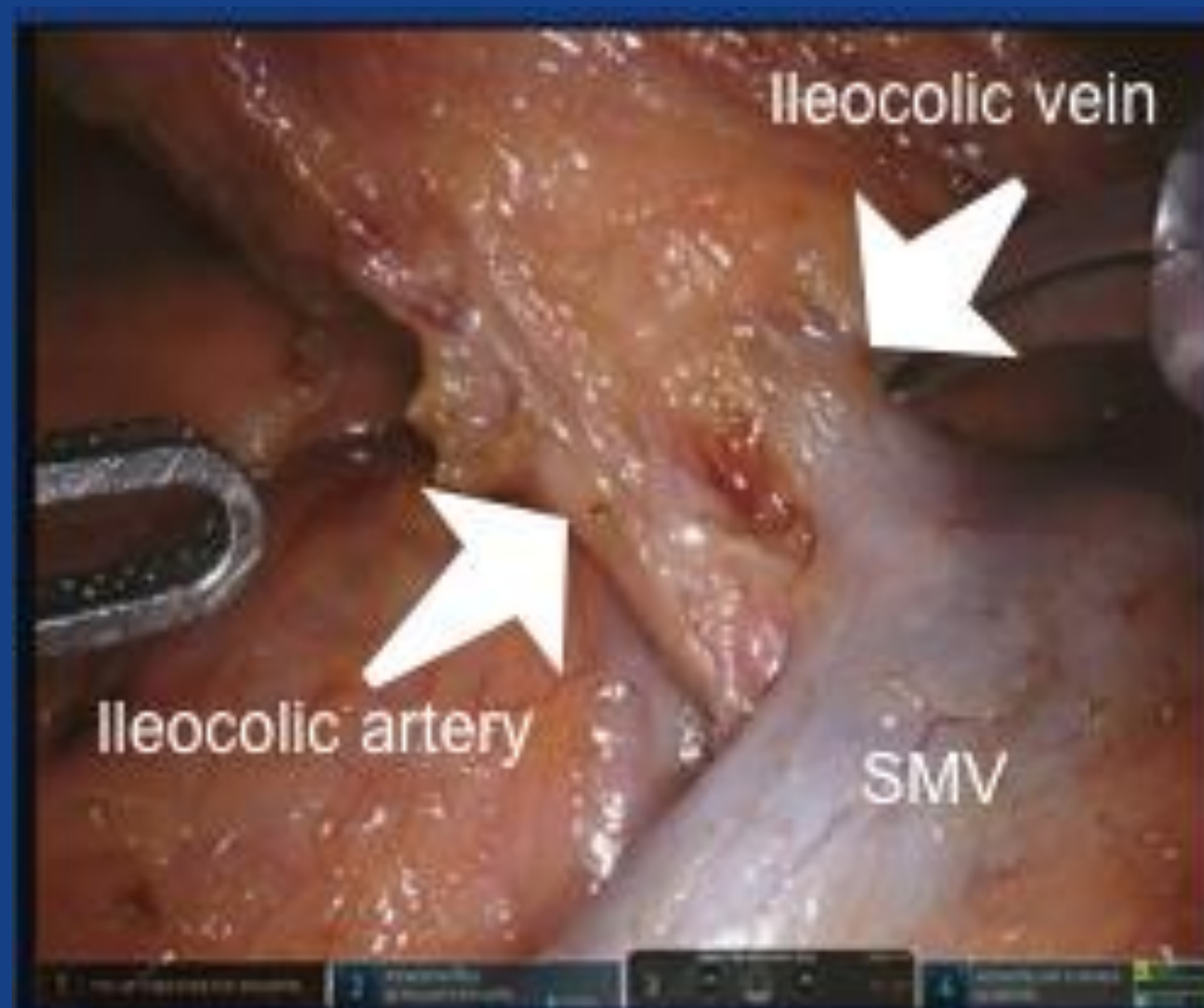Investigations:

- CEA level: 3.4 ug/L (ref <10)
- Gastroscopy: normal
- Colonoscopy: circumferential proximal ascending tumour
- Biopsies: moderately differentiated adenocarcinoma
- Staging CT: abnormal mural thickening at region of caecum with multiple right sided liver lesions. No other metastases (Fig 1).

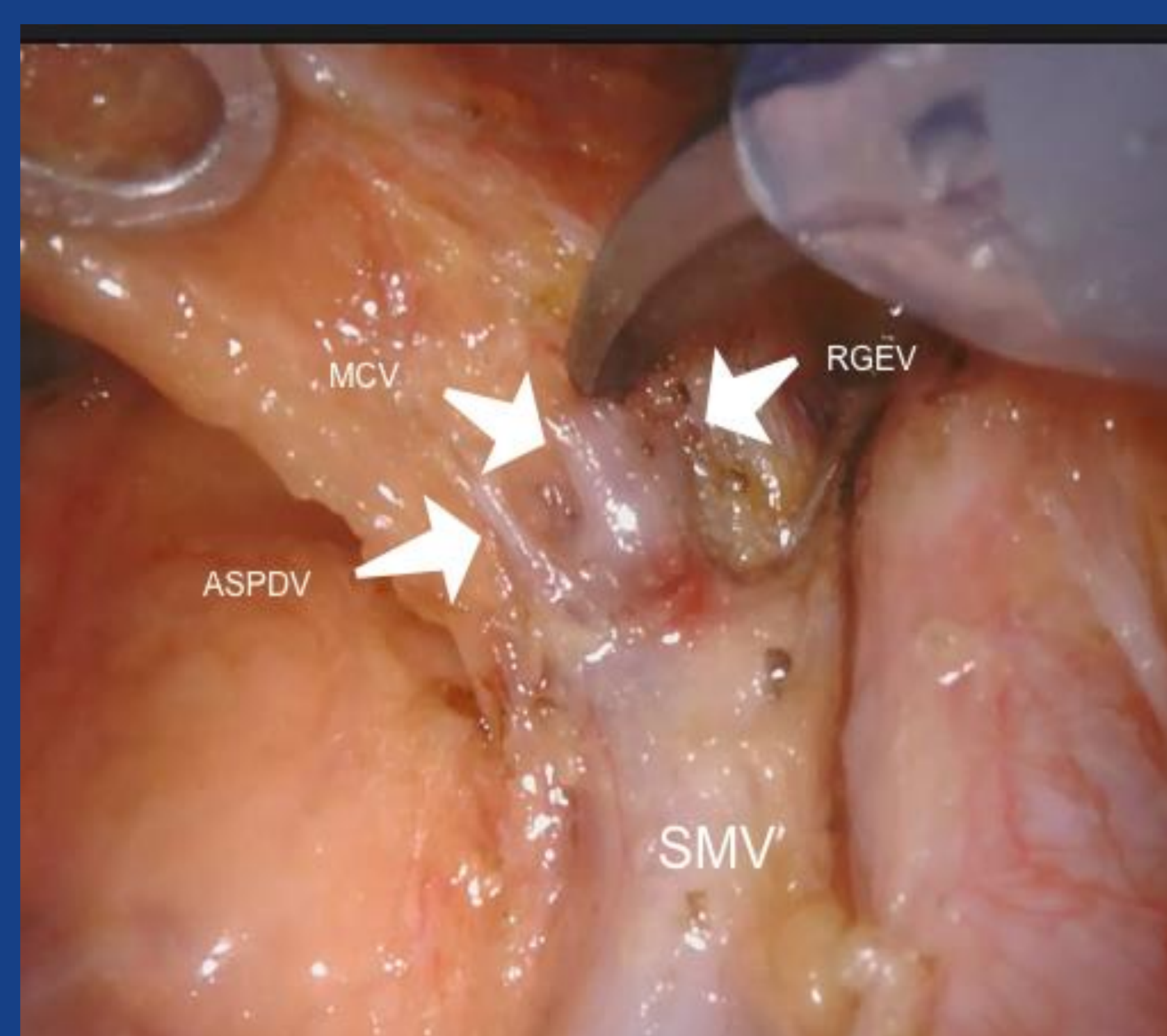
**Fig 1** Coronal C+ with arrow indicating abnormal caecal mural thickening.



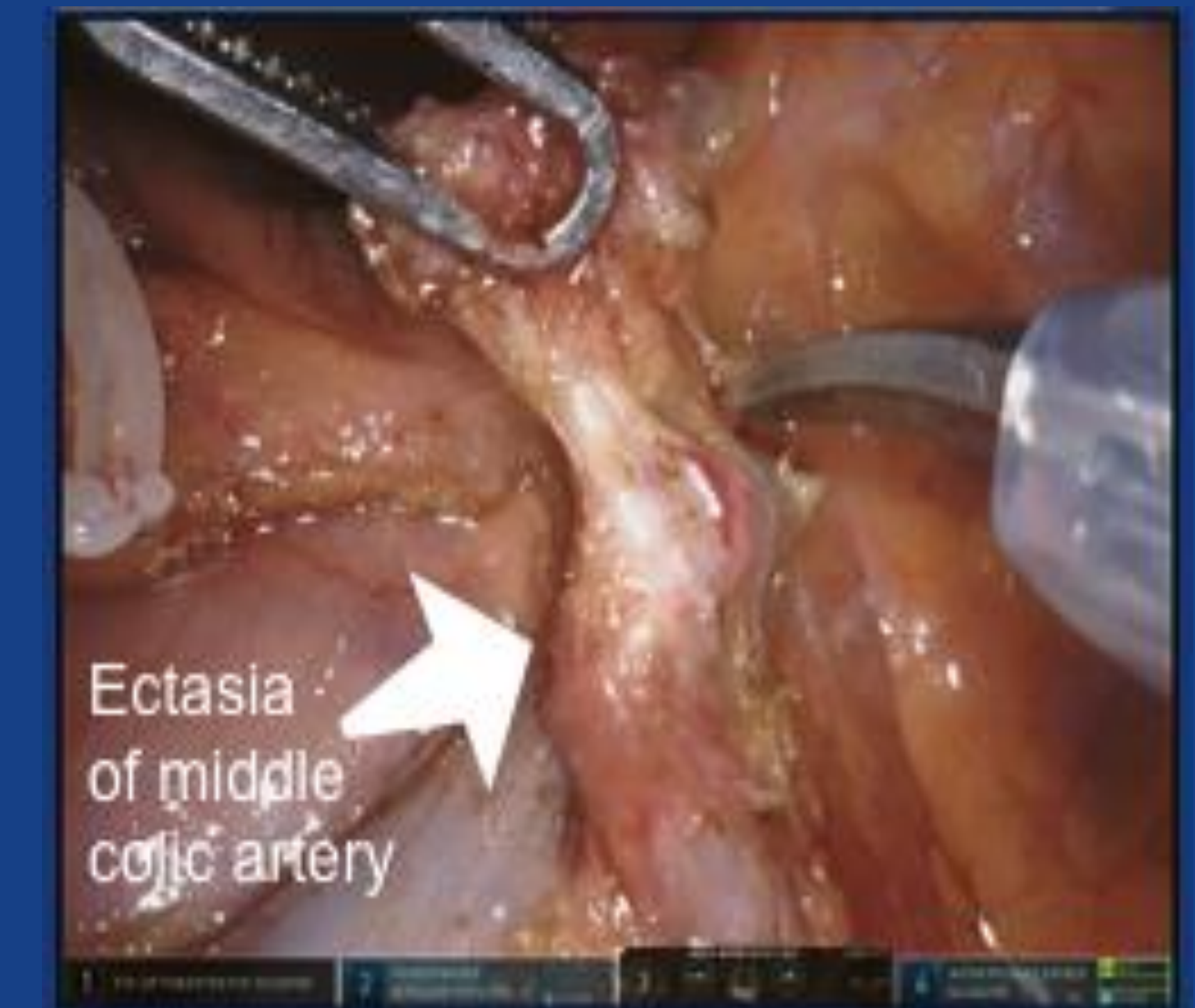**Fig 2** Ileocolic pedicle dissection. Superior mesentery vein, inferior mesentery vein and artery on view.



**Fig 3** Trunk of Henle dissection.



**Fig 4** Dissection of the ectatic middle colic artery.

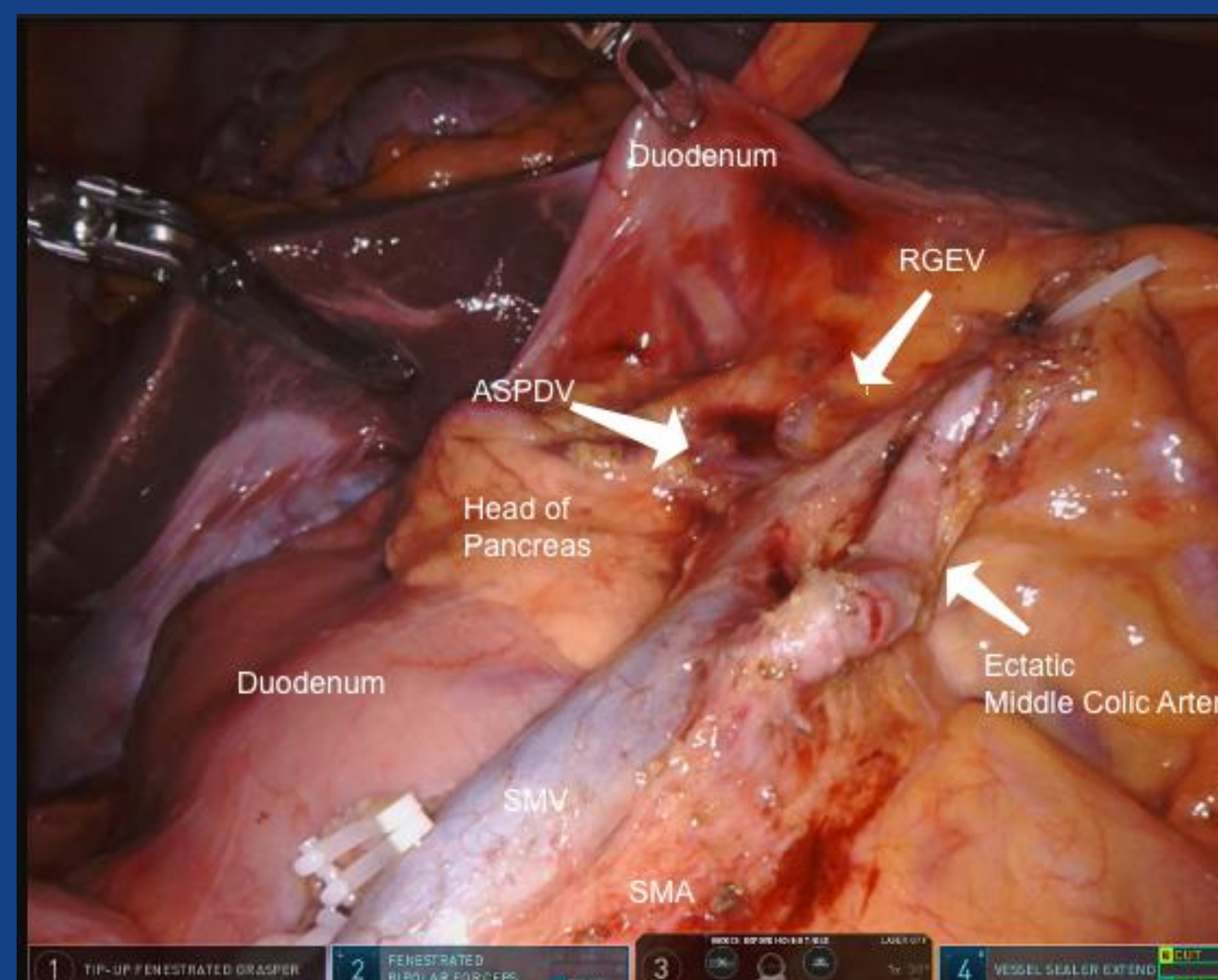


## METHODS

The video demonstrates the following steps:

- SMV-first approach
- Dissection superiorly, along the SMV:
  - Ileocolic pedicle (divided) (Fig 2)
  - Trunk of Henle (colic branch divided) (Fig 3)
  - Ectatic middle colic artery (right branch divided) (Fig 4)
- Dissection of the omentum from the transverse mesocolon and lesser sac entered
- Mobilisation of the ascending colon and hepatic flexure
- Transection of the terminal ileum and transverse colon
- Indocyanine green fluorescence to confirm vascularity (Fig 5)
- Intracorporeal, isoperistaltic anastomosis between terminal ileum and transverse colon

**Fig 6** Dissection of the ectatic middle colic artery.



## DISCUSSION

- Total operative time: 180 minutes
- Discharged day eight post-operatively without complication
- Histopathology: T3N2a moderately to poorly differentiated adenocarcinoma with five out of 33 lymph nodes positive
- This video case study illustrates the advantages of the robotic platform and its safety for robotic right hemicolectomy and central mesocolic excision

## REFERENCES

1. Waters PS, Cheung FP, Peacock O et al. Successful patient-oriented surgical outcomes in robotic vs laparoscopic right hemicolectomy for cancer - a systematic review. *Colorectal Dis* 2020; 22: 488-499.
2. Corcione F, Esposito C, Cucurullo D et al. Advantages and limits of robot-assisted laparoscopic surgery: preliminary experience. *Surg Endosc* 2005; 19: 117-9.
3. Delaney CP, Lynch AC, Senagore AJ et al. Comparison of robotically performed and traditional laparoscopic colorectal surgery. *Dis Colon Rectum* 2003; 46: 1633-9.